

# Enhancing Facial Aesthetics: Integrating Procedures for Profilloplasty Optimization

Alan Macário, BDS; Tâmara Alencar, BDS; Juliana Ramalho, MSc;

BR GREEHOF - IAMAC BR



## INTRODUCTION

Facial harmony plays a crucial role in enhancing the quality of life and emotional well-being of individuals. Profilloplasty, a procedure aimed at improving the facial profile, has gained significant attention in the field of aesthetic dentistry, since the prominence, projection, and proportion of the chin affect facial symmetry, and influences both facial aesthetics and functional harmony, especially in relation to the maxilla and mandible. The objective of this study is to present a clinical case of profilloplasty aimed to enhance the chin projection by utilizing hyaluronic acid injection in two different tissue layers within the same region.

## CASE REPORT

A 33-year-old female patient was admitted for clinical evaluation seeking a solution for an underdeveloped chin.

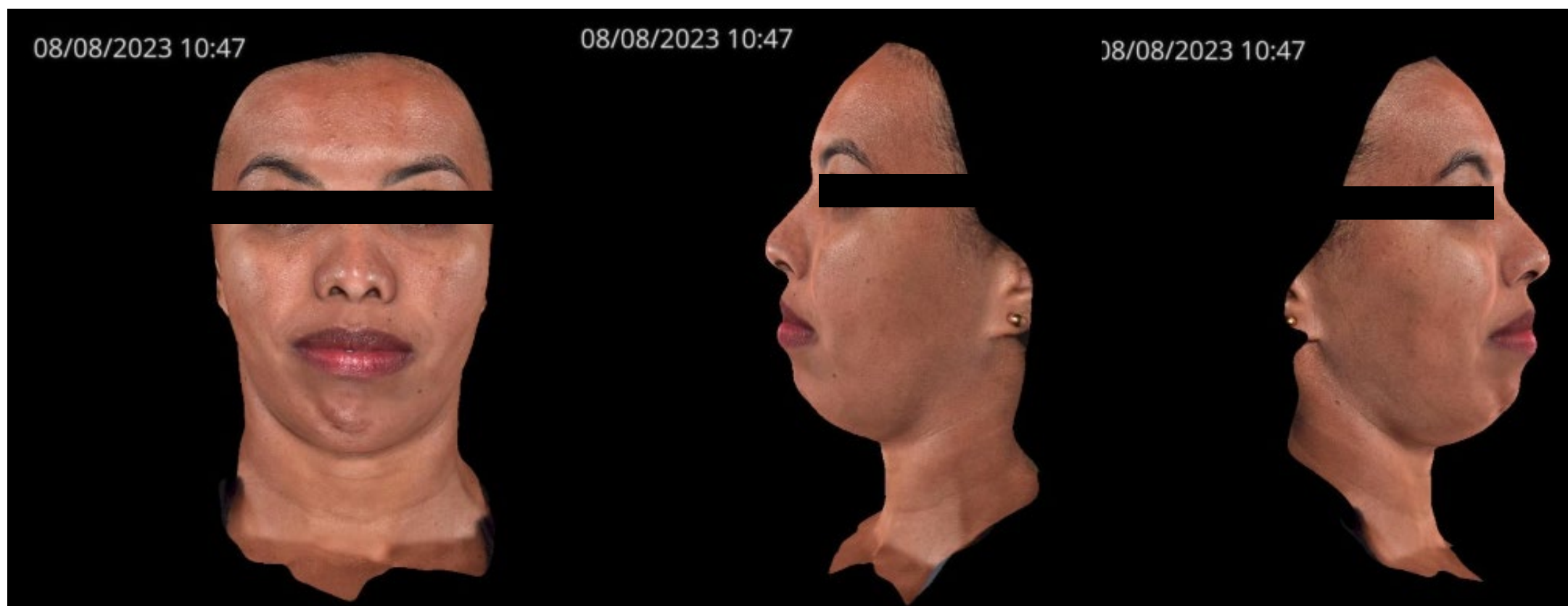

Fig 1. Before treatment: Clinical analysis identified a retrognathic mandibular relation, forward-positioned mentum, and chin volume deficiency

The goal was to enhance the chin's projection vertically and horizontally, along with ensuring tissue stability. The planning process involved 3D scanning and photography to accurately assess the maxilla/mandibular relations and metrics for precise intervention. Clinical analysis identified a retrognathic mandibular relation, forward-positioned mentum, and chin volume deficiency.



Fig 2. QUANTIFICARE LifeViz Mini Classic 3D camera.

Detailed 3D scanning and photography were performed using the QUANTIFICARE LifeViz Mini Classic 3D camera to determine the extent of the issue. This system is a state-of-the-art 3D imaging and measurement technology designed for medical and aesthetic applications. It provides high-quality, accurate, and detailed 3D images of the human body, enabling precise measurements, assessments, and visualizations. The LifeViz technology is particularly useful in fields for aesthetic procedures.

A comprehensive analysis revealed a class II patient with mandibular retrognathism and discrepancy in chin/maxilla relations (Fig 3). The treatment plan necessitated a vertically projected and tissue-stable mentum, requiring a cohesive, high G' product. Additionally, horizontal projection and tissue hydration were needed, requiring a high swelling factor and viscoelasticity product. A combined approach was chosen: 1 ml of highly cross-linked, high G' Rennova Deep Line Lido for vertical projection, and 1.25 ml of Rennova Ultra Deep for volumization.

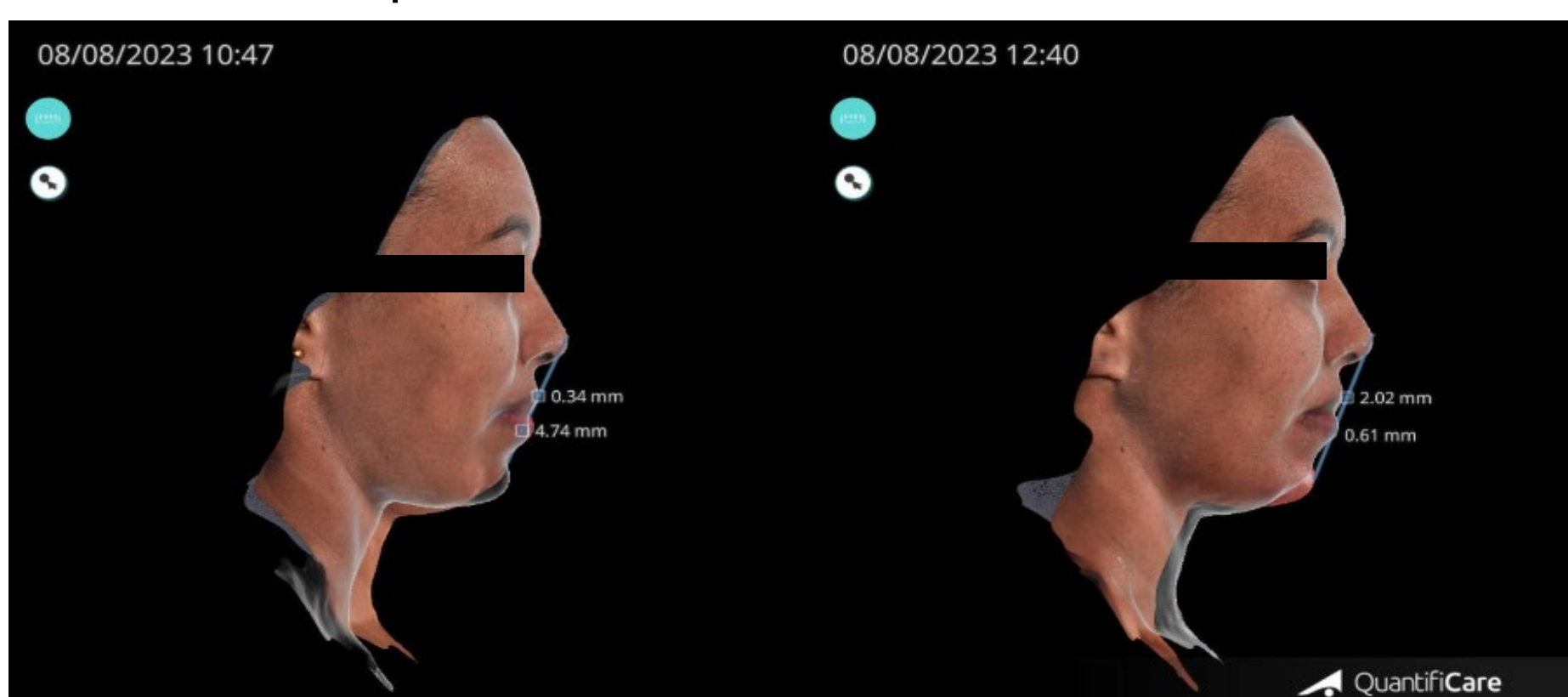


Fig 3. Before and After. The treatment plan was executed as outlined in the figure, with precise injection points and techniques.

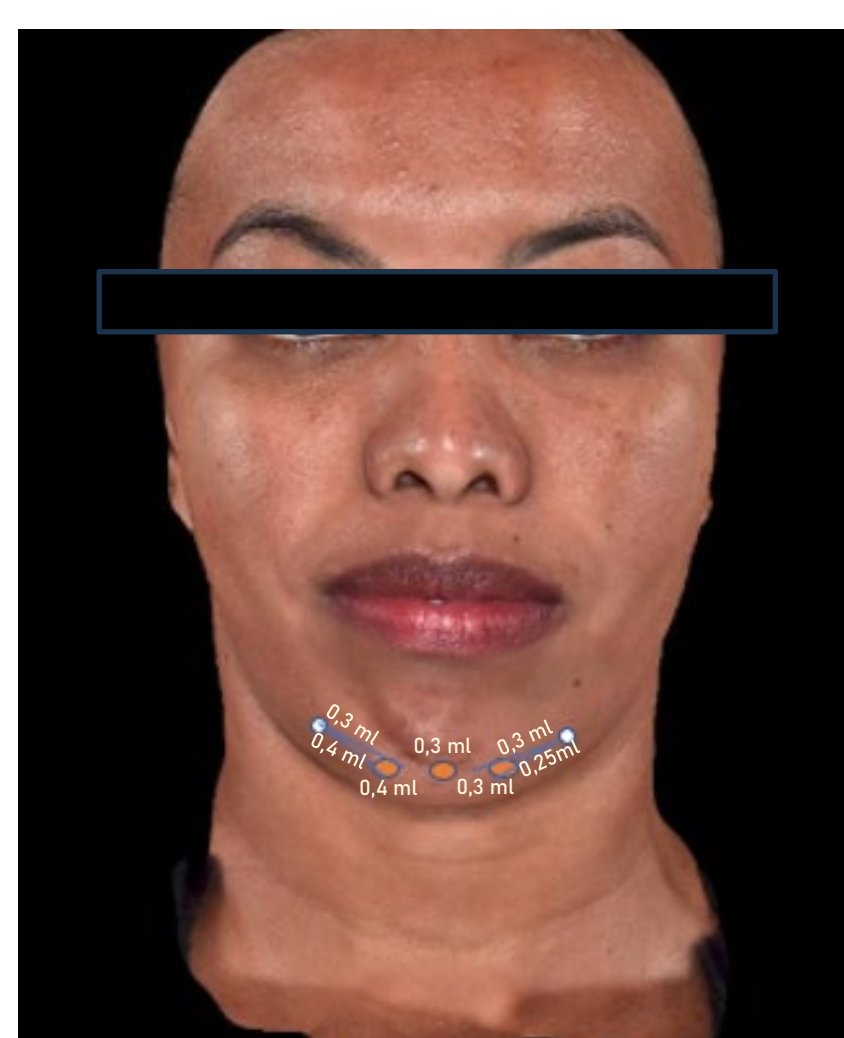

Fig 4. Before treatment. Injection Points and Technique: Hyaluronic Acid injected in the supraperiosteal layer and subcutaneous layer.

Hyaluronic acid injections were administered at 3 points using a needle in the supraperiosteal layer, highlighted in figure 4 by the orange color. Two injections, with a volume of 0.3 ml each, were placed (centrally and on the left side), while the right side received 0.4 ml. A total of 1 ml of the deep line Lido Rennova product was injected. In the subcutaneous layer, a cannula was used, creating two fan-shaped injections on each side. On the right side, a total of 0.7 ml was administered, and on the left side, 0.55 ml was administered, resulting in a total of 1.25 ml of the Rennova Ultra-Deep product (Fig 4).

## RESULTS & DISCUSSION

The profilloplasty procedure utilizing hyaluronic acid filler yielded noticeable improvements in the patient's facial profile. The targeted areas, such as the nasal bridge, chin, or midface region, showed enhanced definition and balance. The filler effectively provided volume and contour, resulting in an aesthetically pleasing outcome (Fig 5).

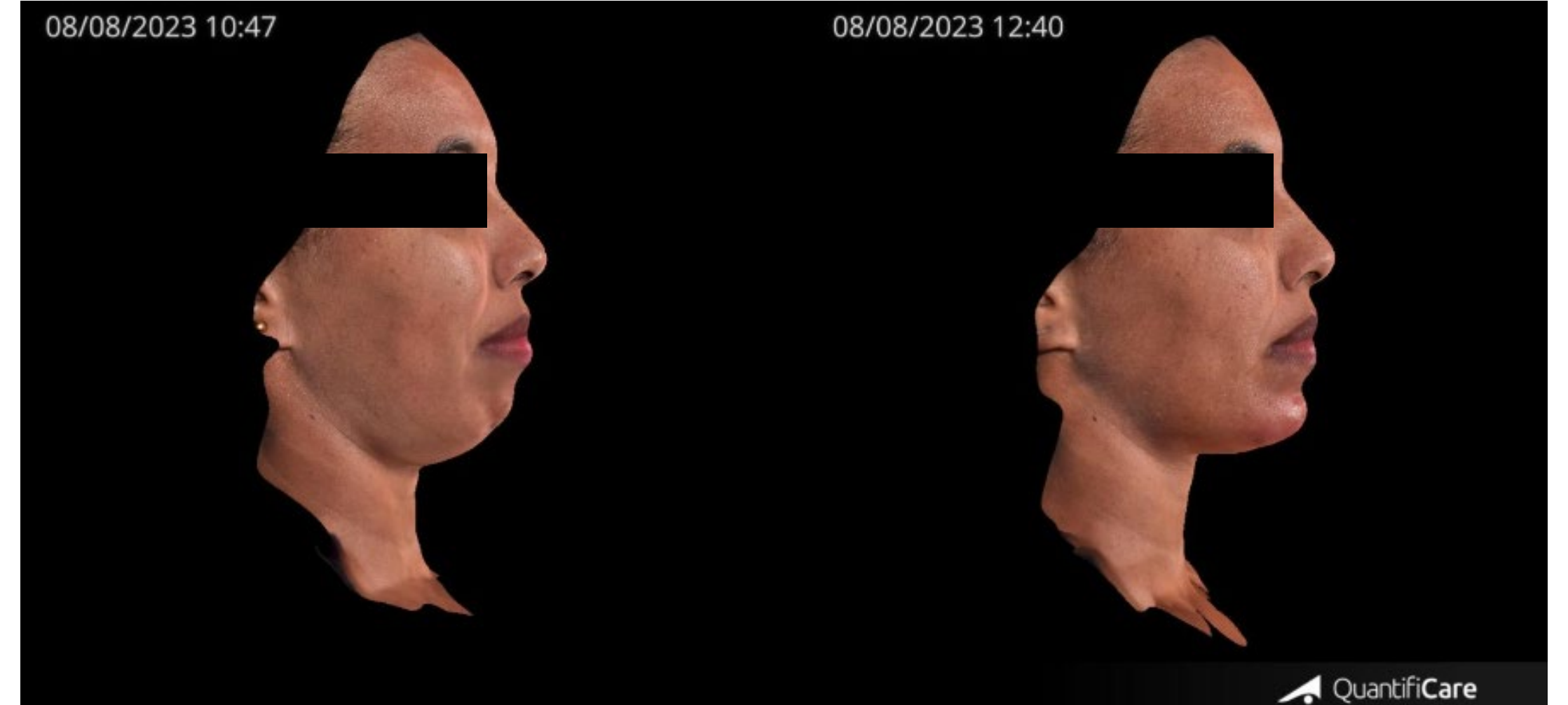

Fig 5. Before and After Photos: Demonstrating Tissue Enhancement and Facial Proportion Alteration Following Hyaluronic Acid Application.

The executed treatment plan successfully achieved vertical projection and volumization of the mentum region as intended. Utilizing Quantificare software, a volumetric gain of 2.41mL was observed in the mentum area. Additionally, a quantified tissue displacement of 27.70mm was observed, indicating effective tissue lifting (Fig 6). The mentum's antero-posterior relation with the maxilla exhibited significant improvement, enhancing overall facial harmony and patient profile.

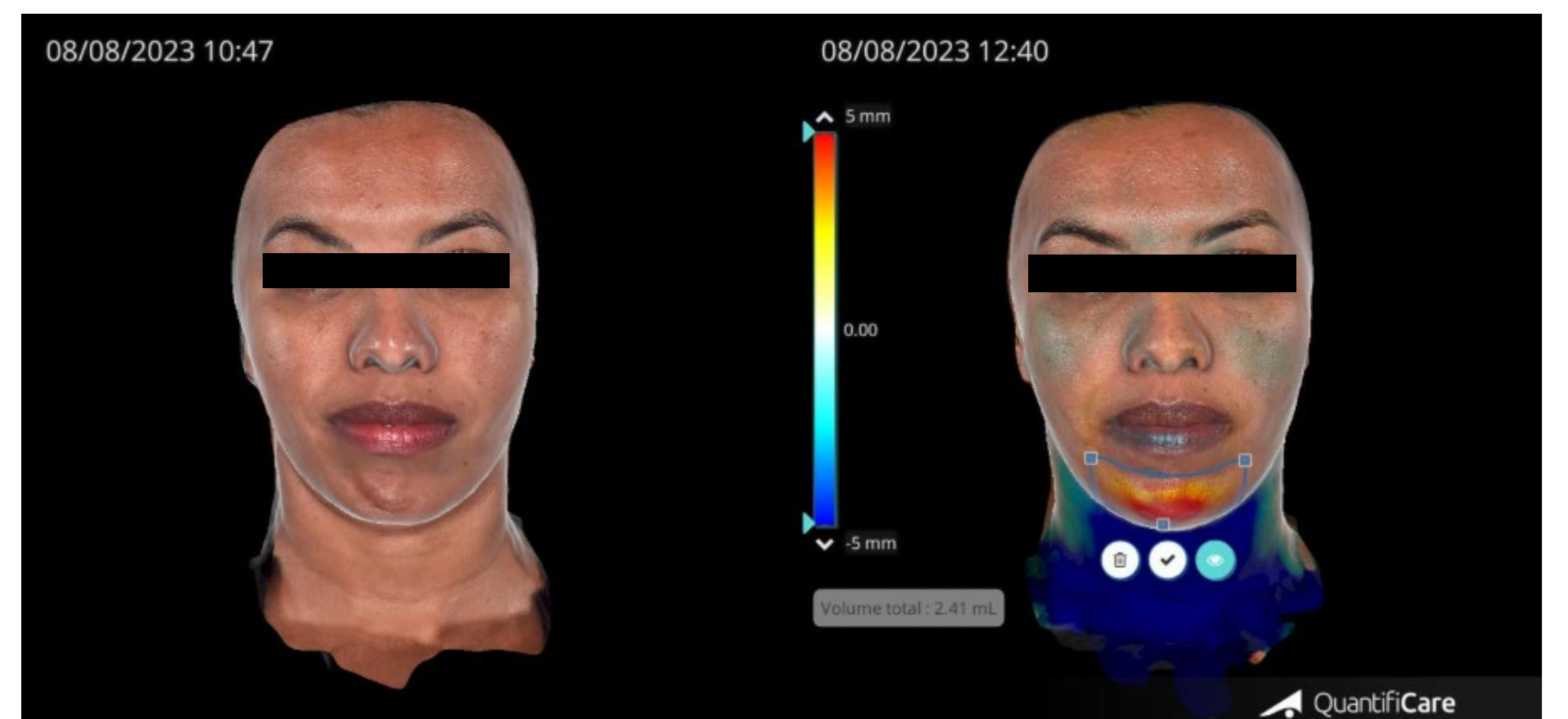


Fig 6. Before and After: Red Marking Highlighting Area of Tissue Volume Enhancement After Hyaluronic Acid Injection.

The advantages of using hyaluronic acid fillers for profilloplasty include their biocompatibility and reversible nature. Hyaluronic acid fillers offer a non-surgical alternative with minimal downtime and immediate results. Additionally, the ability to customize the treatment based on the patient's unique facial features allows for personalized outcomes.

However, it is important to consider the limitations and potential risks associated with profilloplasty using hyaluronic acid fillers. Possible adverse events include bruising, swelling, and rare instances of infection or vascular complications. Patient selection, proper technique, and thorough understanding of facial anatomy are essential to minimize risks and maximize patient satisfaction.

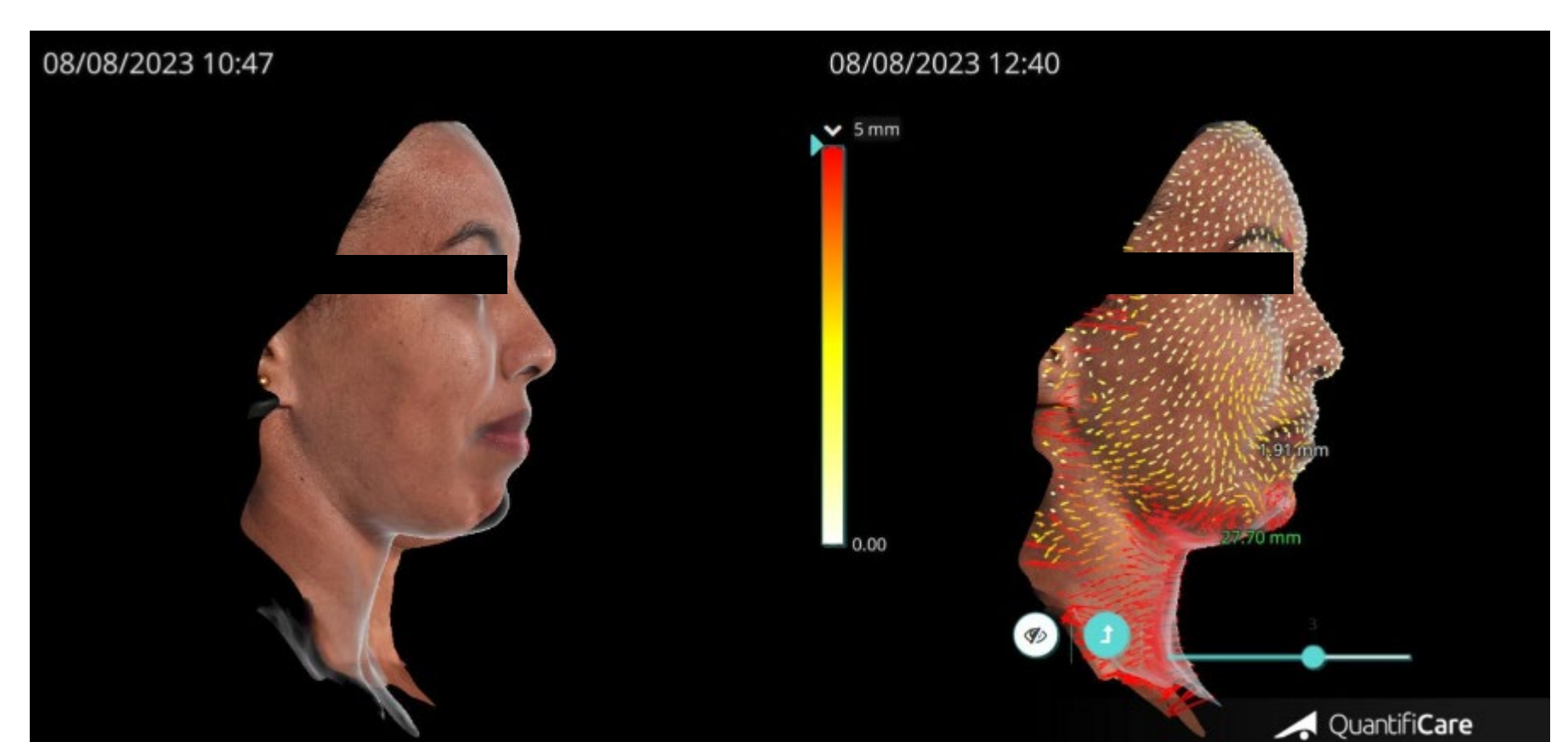


Fig 7. Before and after: Tissue Displacement Post Chin Volume Enhancement

## CONCLUSION

This case study demonstrates the successful utilization of hyaluronic acid fillers for comprehensive chin augmentation. The approach involved a strategic combination of vertical and horizontal projection, along with stable tissue enhancement. The use of Quantificare technology allowed for accurate planning, execution, and quantification of results, highlighting the efficacy of this treatment approach.

## REFERENCES

1. Lazzarotto A, Robiony M, Cambiaso-Daniel J, Nocini R, Gualdi A. Social Profilloplasty: A Practical Assessment and Injection Guide. *Facial Plast Surg.* 2022 Apr;38(2):135-142. doi: 10.1055/a-1789-4621. Epub 2022 May 2. PMID: 35253136.
2. Makram M, Noaman A, Abozeid M. 3D Volume Assessment as an Objective Tool in Breast Asymmetry Management. *Plast Reconstr Surg Glob Open.* 2023 Apr 7;11(4):e4904. doi: 10.1097/GOX.0000000000004904. PMID: 37038412; PMCID: PMC10082228.